




Stony Coral Tissue Loss Disease




Elliptical Star Coral



Dichocoenia stokesii




DSTO




Lobed Star Coral




Orbicella annularis




OANN



Mountainous Star Coral



Orbicella faveolata




OFAV




Large Cup Star Coral



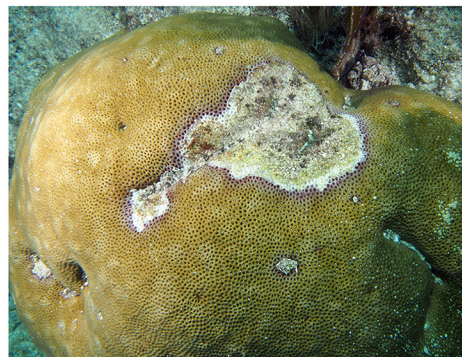
Montastraea cavernosa




MCAV



Starlet Coral



Siderastrea siderea




SSID



Stony Coral Tissue Loss Disease

HEALTHY


DISEASED



DSTO




Dichocoenia stokesii




DSTO


Elliptical Star Coral



OANN

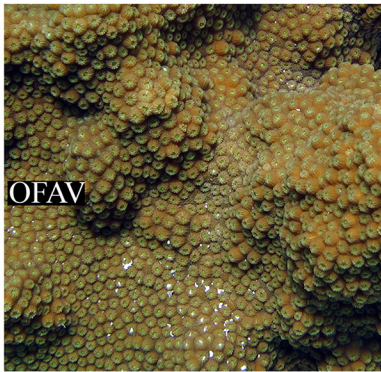


Orbicella annularis



OANN

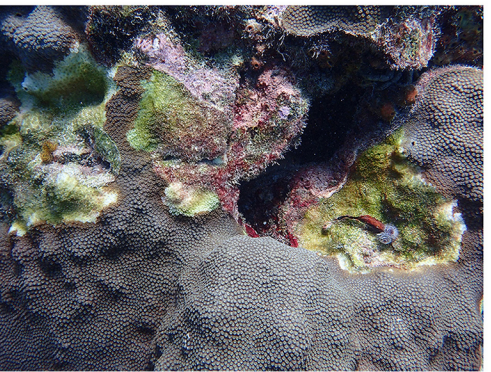
Lobed Star Coral



OFAV

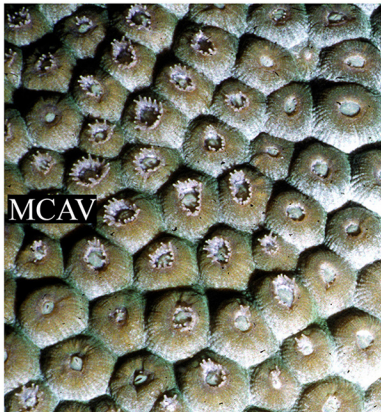

Orbicella faveolata




OFAV


Mountainous Star Coral



MCAV

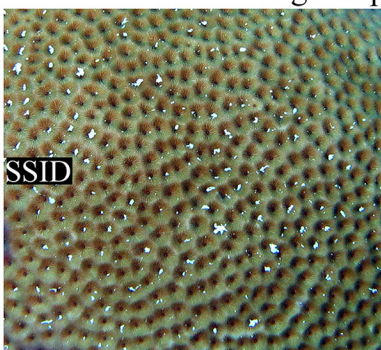


Montastraea cavernosa



MCAV


Large Cup Star Coral



SSID



Siderastrea siderea



SSID

Starlet Coral

Andrew Bruckner, FKNMS

